

Multidisciplinary Treatment Maximizes Outcomes for Malignant Tumors of the Anterior Skull Base

By Joe Munch

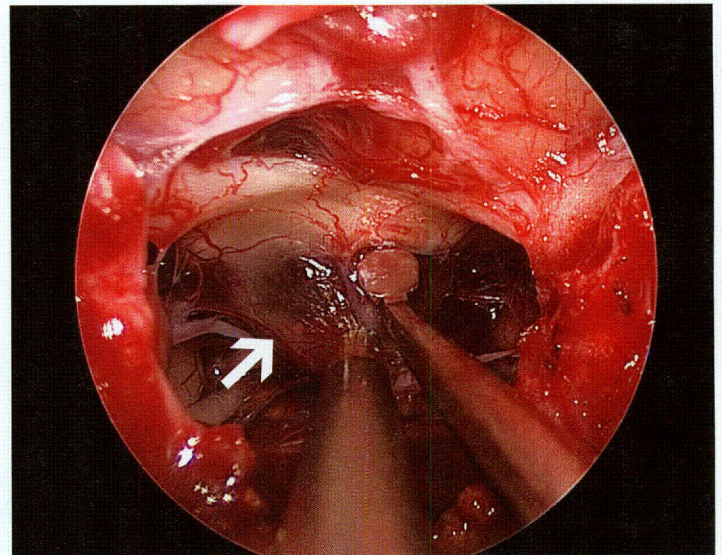
Malignant tumors of the anterior skull base occur in a delicate area but often need aggressive treatment. Determining the best course of therapy for patients with these tumors takes a multidisciplinary effort.

"These patients require comprehensive, coordinated treatment," said Franco DeMonte, M.D., a professor in the Department of Neurosurgery at The University of Texas MD Anderson Cancer Center. "There are so many nuances in pathology and imaging and so many complexities in deciding which surgical approach to use, how to target the radiation therapy, which form of radiation to use, and whether to give chemotherapy before or after surgery—no single person is a repository of all that information."

"At MD Anderson, we have everybody involved up front," said Renata Ferrarotto, M.D., an assistant professor in the Department of Thoracic/Head and Neck Medical Oncology. "These patients are always seen by surgeons, medical oncologists, and radiation oncologists; and we discuss their cases as a team."

Initial decisions

Malignant tumors of the anterior skull base are rare but include a wide range of cancers, including those originating



Surgeons visualize a craniopharyngioma (arrow) below the optic chiasm during an endoscopic resection. Image courtesy of Dr. Franco DeMonte.

in or at the skull base (e.g., chordoma and chondrosarcoma) and those originating elsewhere and invading the skull base (e.g., adenoid cystic carcinoma, esthesioneuroblastoma, and nasopharyngeal carcinoma). Because this variation lends itself to a high incidence of incorrect or inconclusive diagnoses, experienced pathologists are essential to correctly identify the disease.

In most patients, a tumor sample is obtained via endoscopy; image-guided fine-needle aspiration also can be used to obtain a biopsy specimen. Additional diagnostic information, most importantly the extent of the tumor, is obtained

Open vs. Endoscopic Approach

Less invasive surgery appropriate for some skull base tumors

3

Eyelid and Conjunctival Tumors

Innovative techniques preserve function

5

House Call

Smoking causes health problems besides cancer

7



THE UNIVERSITY OF TEXAS
MDAnderson
Cancer Center

Making Cancer History®

Anterior Skull Base Tumors

[Continued from page 1]

by computed tomography and/or magnetic resonance imaging. The histologic type and the extent of the tumor help determine the types of therapies used.

The vast majority of malignant skull base tumors are treated with definitive surgery.

"The first question is whether the tumor is resectable with acceptable morbidity," Dr. DeMonte said. "Determining this involves a neurosurgeon and a head and neck surgeon primarily. Input from a plastic surgeon is crucial if large amounts of tissue are to be removed." If the tumor is considered to be resectable, Dr. DeMonte said, the next question is whether neoadjuvant chemotherapy should be given. If the tumor is small, is compartmentalized, and appears to be resectable, the patient may undergo surgery first. But if the tumor is extensive—invading the orbit, for example—neoadjuvant chemotherapy may be given with the goal of shrinking the tumor to make it more amenable to resection.

Whether neoadjuvant chemotherapy is given also depends on the tumor pathology. "Some of these tumors—like high-grade neuroendocrine carcinomas, sinonasal undifferentiated carcinomas, or squamous cell carcinomas—are very sensitive to chemotherapy," Dr. Ferrarotto said. "But others, like adenoid cystic carcinomas and chondrosarcomas, are resistant; so we rarely use chemotherapy for those types of tumors because the chance of response is very small."

When neoadjuvant chemotherapy is used, the tumor's response can determine the treatment course. Patients with a complete response do not need to undergo surgery; they may receive radiation therapy instead. Patients with a partial response usually undergo resection of the residual tumor followed by radiation therapy. Patients with no response, depending on the situation, may need surgery or definitive chemoradiation.

Five goals of surgery

According to Ehab Hanna, M.D., a professor in the Department of Head

"[W]e want these patients to be able to walk down the street without anyone knowing from looking at them that they've had a skull base resection."

— Dr. Ehab Hanna

and Neck Surgery, surgery for a malignant tumor of the anterior skull base has five main goals. The first goal, complete oncologic resection of the tumor, is by far the most important because it has a direct correlation with survival. The second goal is to protect critical structures.

"This area is replete with what we call high-stakes real estate," Dr. Hanna said. "There's the optic nerve, the carotid artery, the spinal cord, and cranial nerves that control speaking, swallowing, and breathing—essentially a lot of nerves and vessels that have very critical functions. Preserving these neurovascular structures is important because doing so directly translates into functional preservation and better quality of life."

The third goal of surgery is to minimize manipulation of the brain. Excessive retraction of brain tissue can cause brain swelling, which in turn delays recovery and affects some of the subtleties of emotion, memory, and personality.

The fourth goal is meticulous reconstruction of the anterior skull base and dura, which serve as a wall between the intra- and extracranial components of the head. "The dura and skull base need to be watertight," Dr. Hanna said. "Spinal fluid leakage from the intracranial component can allow bacteria to invade and cause meningitis, and that complicates the postoperative course significantly."

The final goal is optimal aesthetic outcome, for which the endoscopic ap-

proach is superior when indicated (see "Choosing an Open or Endoscopic Approach," p. 3). "But when an open approach is needed, we mobilize all of our teams—the head and neck team, the neurosurgical team, the maxillofacial dental team, the plastic and reconstructive team—we want these patients to be able to walk down the street without anyone knowing from looking at them that they've had a skull base resection," Dr. Hanna said.

The length of surgery tends to vary according to the number of services involved. Surgeries involving only head and neck surgery or neurosurgery can last 2 or 3 hours; those involving both services can last 5 or 6. When reconstructive surgery is added, the surgery can last a dozen hours or more. Whether the tumor involves the intracranial, the extracranial, or both compartments determines which services are involved. Intracranial tumors are removed by a neurosurgeon, whereas extracranial tumors are removed by a head and neck surgeon. The two surgical teams work together to remove tumors transgressing from the intracranial to the extracranial compartment or vice versa.

"The sequence in which the two teams work to remove the transgressing tumor isn't important, but the concept is the same. By compartment, you need a bidirectional view; you need to look from the bottom, and you need to look from the top," Dr. Hanna said. "It's only when you have both sides of the exposure that you can safely cut out the tumor without injuring the critical structures nearby."

Radiation therapy delivery

Like surgery, radiation therapy is used for local disease control in patients with malignant tumors of the anterior skull base. Radiation can be given alone to treat unresectable tumors that are highly unlikely to respond to neoadjuvant chemotherapy, or it can be given with or without concurrent chemotherapy to treat unresectable tumors or as an adjuvant to surgery for highly aggressive tumors.

Several approaches—including conventional external-beam, stereotactic, and intensity-modulated radiation therapy—can be used in the skull base area. Each approach is employed with the intent of eradicating as much of the cancer as possible while avoiding brain necrosis, which can give rise to cognitive dysfunction, and sparing structures essential to hearing, vision, smell, and taste.

“When we’re considering which radiation therapy approach we want to use in one of these patients, we’re looking at the tumor histology, we’re looking at the surrounding normal tissues, and we’re looking at how much of a radiation dose is required to eliminate the cancer,” said Steven Frank, M.D., an associate professor in the Department of Radiation Oncology. “And then we’re trying to piece that information together to determine the best tool that will allow us to achieve a high level of cure with minimal side effects.”

Both photon and proton radiation therapy can be used to treat these tumors. Whether one or the other is selected usually depends on the effective radiation dose that must be safely delivered to the tumor. In general, the higher the radiation dose needed, the greater the risk to surrounding healthy tissue and the more precise the radiation delivery must be. Unlike photons, which continue to pass through the body after they have hit the targeted tumor, protons can be made to stop within the targeted tumor, thereby reducing damage to surrounding healthy tissues and enabling higher doses of radiation to the tumor.

“If we need to give a high radiation dose to achieve disease cure without compromising the surrounding tissue, we would consider proton therapy,” Dr. Frank said. “Normal brain tissue might not tolerate a high dose given with photon therapy, which could cause brain necrosis or other problems.”

Indeed, the role of proton therapy in the treatment of malignant skull base tumors is increasing, due in large part to the work of Dr. Frank and his colleagues at MD Anderson’s Proton Ther-

Choosing an Open or Endoscopic Approach

owing to recent advances in instrumentation and surgical field visualization, endoscopic surgery is becoming an increasingly viable alternative to traditional open craniofacial surgery in patients with malignant tumors of the anterior skull base. Endoscopic surgery has, for example, almost completely eliminated the need for facial incisions for the removal of malignant tumors of the clivus, and its value in the treatment of sinonasal malignancies has been shown in research done at MD Anderson. Endoscopic surgery is not appropriate for every patient, however.

“It might be considered in vogue to do the minimal access surgery, but if it doesn’t take the tumor out completely, then it’s the wrong thing—it’s potentially lethal, in fact,” Dr. Hanna said.

Tumors that have significant brain or orbit involvement and those that have invaded structures whose resection is necessary to achieve negative margins—e.g., the facial skeleton, skin, and/or soft tissues of the face—are not amenable to endoscopic surgery and must be resected using an open approach. Tumors that extend beyond the inner third of the orbit and those immediately behind the nasal bone, which cannot be adequately visualized or manipulated endoscopically, must also be resected via an open approach.

“One would think that having a slender tube slid up your nose is better than having an incision, but not necessarily,” Dr. DeMonte said. “The risk profiles of these approaches are different. For example, endoscopic surgery carries a significantly increased risk of spinal fluid leakage and infection after surgery compared with the open cranial operation.”

According to Drs. DeMonte and Hanna, the key to the successful surgical treatment of patients with malignant tumors of the anterior skull base is knowing both when and how to pursue either approach.

“The real strength of our program is that we are not wedded to one surgical approach or technique,” Dr. Hanna said. “We can pick and choose the right approach for the right patient for the specific tumor they have.” ■

apy Center. One exciting development in this vein is the use of intensity-modulated proton therapy, a form of scanning beam radiation therapy that can be used to precisely deliver large doses of radiation to tumors embedded among critical structures.

“Just as we’ve advanced the delivery of photon therapy in a number of ways, now we’re advancing the delivery of proton therapy, defining its role not only in the skull base and other areas of the head and neck but in other areas of the body as well,” Dr. Frank said.

“These patients are always seen by surgeons, medical oncologists, and radiation oncologists; and we discuss their cases as a team.”

– Dr. Renata Ferrarotto

Anterior Skull Base Tumors

[Continued from page 3]

“The rapid advancement of this technology is occurring before our very eyes.”

Chemotherapy and targeted therapy

In the treatment of patients with malignant tumors of the anterior skull base, the role of cytotoxic chemotherapy is largely limited to the neoadjuvant and concurrent treatment settings. “Sometimes we’ll give chemotherapy up front to shrink the tumor, and after surgery, we might give chemotherapy concurrently with radiation,” Dr. Ferrarotto said. “For unresectable tumors, definitive concurrent chemoradiation is a frequently used approach.”

Given the rarity of malignant anterior skull base tumors, Dr. Ferrarotto said, it’s largely infeasible to do clinical trials to test the efficacy of new agents or hone the delivery of existing agents, and this has hindered the expansion of medical therapy for these tumors. However, some promising preclinical data suggest that targeted therapies may soon have a role. For example, Dr. Ferrarotto and her colleagues found that 13% of adenoid cystic carcinomas, which arise in the secretory glands but can involve the skull base, have Notch-1 activating mutations. “Typical adenoid cystic carcinoma tends to be a very indolent disease, but the Notch-1 mutants are different—patients usually present with advanced-stage disease, they have a propensity to develop liver and bone metastasis, and they have a much worse prognosis,” Dr. Ferrarotto said. “It might be that this group would benefit from targeted systemic therapy, particularly Notch-1 inhibitors.”

Dr. Ferrarotto’s group is now looking into whether other skull base tumors have Notch-1 mutations. Other therapeutic targets are also being investigated.

For example, Dr. Ferrarotto said, poly(ADP-ribose) polymerase (PARP) inhibitors are being studied in neuroendocrine tumors that occur in the skull base. She said these preclinical studies

[Continued on page 8]

Management of Eyelid and Conjunctiva Tumors Preservation of Sight, Function

By Bryan Tutt

Tumors of the eyelid and conjunctiva vary in histology and extent of disease, and which treatments, if any, are needed after surgical excision depends on several factors, including the potential for metastasis.

To help guide treatment decisions, physicians at The University of Texas MD Anderson Cancer Center are using innovative techniques such as sentinel lymph node biopsy (SLNB) to refine the staging of these tumors and are conducting molecular studies of rare tumors to improve the personalized treatment of patients with eyelid and conjunctival tumors.

“Treating cancers of the eyelid and conjunctiva requires a multidisciplinary effort that includes surgeons, nuclear radiologists, pathologists, and radiation and medical oncologists,” said Bitá Esmaeli, M.D., a professor of ophthalmology and the director of the Orbital Oncology and Ophthalmic Plastic Surgery Fellowship Program at MD Anderson.

Dr. Esmaeli said that the first-line treatment for eyelid or conjunctival tumors is almost always surgical excision, although radiation therapy may be used as the first-line treatment if surgery is contraindicated. In patients whose tumors are excised, decisions about postoperative treatment are determined by factors such as the type of cancer and the risk of lymph node metastases.

Surgery and reconstruction

Many eyelid and conjunctival tumors are caught early; such tumors often

can be excised and the wound repaired using oculoplastic surgical techniques with little or no loss of eye function. Neither enucleation nor orbital exenteration has been shown to improve survival outcomes, so these procedures are unnecessary unless there is orbital extension of the tumor. However, large tumors can endanger function and require extensive reconstruction, and surgeons at tertiary referral centers often encounter such difficult-to-treat cases. “We see rare cancers of the eyelid at an advanced stage, where it is questionable whether we can salvage the eye and its function. Such cases are where complex reconstructive procedures and an innovative but cautious multidisciplinary approach can make a big difference,” Dr. Esmaeli said.

At MD Anderson, reconstructive surgery typically is performed immediately after the tumor is excised. A tumor’s size and location determine the techniques used for reconstruction. “Basal cell carcinoma most often occurs in the lower eyelid, and for the larger tumors the wound from excision is repaired with a tarsoconjunctival flap [Hughes flap]—often with excellent functional and cosmetic outcomes,” Dr. Esmaeli said. “But the more rare cancers—sebaceous carcinoma, melanoma, and Merkel cell carcinoma—tend to occur in the upper eyelid, which is more difficult to reconstruct. Patients with these tumors are more likely to come to a referral center, and as a result we end up doing more of these unusual, upper eyelid reconstructions compared with other settings. Eyelid sharing procedures such as Cutler-Beard bridge flaps are often needed to reconstruct large upper eyelid defects.”

Conjunctival carcinomas and melanomas, which can occur in either the bulbar or palpebral region, typically require microscopic ocular surface reconstruction and sometimes the use of amniotic membrane grafts. Special handling of conjunctival surgical specimens by the pathologist and communication between the eye surgeon and the

Conjunctival Tumors with Lymph Node Metastasis and Cosmesis

pathologist are very important for correct diagnosis of conjunctival melanomas and carcinomas and for determining the patient's prognosis.

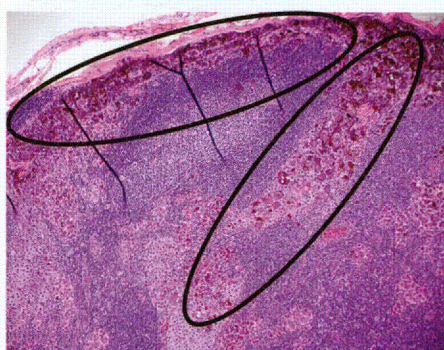
For tumors that have a significant risk of regional lymph node metastasis—such as conjunctival or eyelid melanomas that are thicker than 1 mm or demonstrate other high-risk histologic features such as ulceration or high mitotic figures, sebaceous carcinomas of the eyelid, or Merkel cell carcinomas of the eyelid—SLNB is typically done at the time of primary tumor excision.

Sentinel lymph node biopsy

SLNB entails the removal and examination of one or two sentinel lymph nodes (i.e., the draining lymph nodes nearest the tumor) to determine whether they contain metastatic disease. The use of SLNB for eyelid and conjunctival cancers was developed and modified over the past 15 years by Dr. Esmaeli and her colleagues at MD Anderson—including Merrick Ross, M.D., a professor in the Department of Surgical Oncology, and Jeffrey Myers, M.D., Ph.D., a professor in the Department of Head and Neck Surgery. The technique has now been adopted at other centers, mostly outside the United States.

“The chief benefits of SLNB are accurate staging and early diagnosis of metastatic disease. In melanomas and other cutaneous tumors of the eyelid and conjunctiva with a significant risk of nodal metastasis, it is important to identify micrometastases early rather than wait for them to get big enough to be palpable on a physical exam or show up on imaging,” Dr. Esmaeli said. “If we can find metastasis early, we can offer treatments earlier.”

Several decades ago, studies were done of elective neck dissection in patients with head and neck cutaneous melanoma. The procedure was abandoned for patients with no signs of metastasis because the morbidity of such major surgery was not justified by the small proportion of patients who



Metastatic melanoma cells (circled) are shown in two lymph nodes. Top: The melanoma cells are limited to the periphery of the lymph node. Bottom: The melanoma cells have extended into the lymph node's parenchyma, indicating a worse prognosis. (Hematoxylin and eosin stain.) Image courtesy of Dr. Victor Prieto.

were found to have positive lymph nodes.

Another drawback of elective neck dissection is the number of lymph nodes that must be examined. “The techniques we use to examine lymph nodes are exhaustive and expensive,” said Victor Prieto, M.D., Ph.D., a professor in and chair of the Department of Pathology. “It would be unfeasible to apply them to up to 30 lymph nodes that can be retrieved in a procedure to remove all the lymph nodes of an anatomic region. With SLNB, by examining only the nodes that are most likely to be positive, we can increase our sensitivity.”

Procedure

Sentinel lymph node(s) typically are removed at the time of primary

eyelid/conjunctival tumor excision, although SLNB can also be done later. Before surgery, a radioactive tracer such as technetium-99m is injected into the tissue around the tumor. Preoperative lymphoscintigraphy may be performed to determine which of the region's multiple nodal basins contains the sentinel node(s). Lymphoscintigraphy can be especially helpful in patients with scarring from prior surgery or radiation therapy.

To remove the sentinel lymph node(s), the surgeon first uses a gamma probe to locate the tracer taken up by the sentinel node(s). A small incision is made, and the sentinel node(s) are removed and sent to pathologists for examination.

Pathologists cut the lymph node into multiple slices, like a bread loaf, rather than in half longitudinally. “In 2002 we proved that the two techniques are equivalent,” Dr. Prieto said. “The advantage of the bread loaf technique is that you can put more tissue in one cassette, so it's less expensive and requires less time to process.”

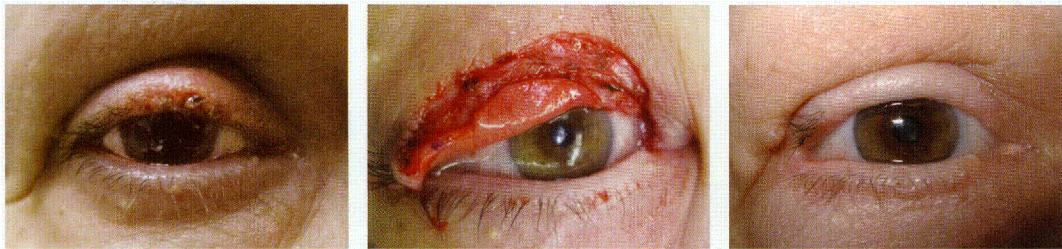
Next, the pathologists look at a slide stained with standard hematoxylin and eosin. If they find tumor cells, the lymph node is positive and no further tests are needed. If hematoxylin and eosin staining is negative, more sensitive immunohistochemical analysis is employed using antigens against the patient's cancer type. For example, antigens against keratin are used for carcinoma and antigens against melanocytes for melanoma. “The test is sensitive enough to detect one cancer cell among thousands of benign cells,” Dr. Prieto said.

Interpretation

The utility of SLNB goes beyond merely stating whether the node is positive or negative: the size of a metastasis and its location within the lymph node also affect the patient's prognosis. “The bigger the metastasis, the worse the prognosis,” Dr. Prieto said. A metastasis deep inside the lymph node's parenchyma carries a worse prognosis than

Eyelid and Conjunctival Tumors

[Continued from page 5]



Left: An upper eyelid tumor is shown before surgery. Middle: The eyelid tumor has been excised, and surgeons prepare to repair the surgical wound. Right: The reconstructed eyelid has excellent function and cosmesis. Image courtesy of Dr. Bitá Esmaeli.

does one on the periphery of the node. Likewise, a metastasis that extends beyond the node's outer capsule carries a worse prognosis than does one contained within the capsule. "If any of the three applies—large size, parenchymal location, or extracapsular extension—the patient has a worse prognosis," Dr. Prieto said.

Postoperative treatment

If the SLNB result is negative, many eyelid cancers require no further treatment after surgery.

However, some conjunctival and eyelid cancers are treated postoperatively (or receive primary or neoadjuvant treatment) with topical chemotherapy drops—mitomycin C for melanoma or sebaceous carcinoma and interferon or 5-fluorouracil for squamous cell carcinoma on the ocular surface—regardless of lymph node status.

In addition, certain tumor characteristics warrant postoperative radiation therapy regardless of lymph node status. Patients with basal cell carcinoma or squamous cell carcinoma may undergo adjuvant external-beam radiation therapy to the periocular region if their primary tumors have high-risk features such as microscopic perineural invasion. Postoperative external-beam radiation therapy is also often recommended for patients with Merkel cell carcinoma of the eyelid to reduce the likelihood of local recurrence, as long as radiation therapy is not expected to endanger the eye. Radiation therapy is generally avoided for tumors of the upper eyelid due to concerns about toxic effects to the eye.

Patients with any type of eyelid or conjunctival cancer whose SLNB results

are positive typically undergo a parotidectomy and completion neck dissection. If such dissection yields three or more positive lymph nodes, radiation therapy to the lymph nodal basin may be recommended. Adjuvant chemotherapy may be recommended for patients with one or more positive nodes.

Positive lymph node status changes a patient's cancer stage, which may make the patient eligible for clinical trials of new agents. Even in the absence of immediate treatment, patients with positive lymph nodes and no evidence of distant metastases are monitored closely so that any metastases that develop can be caught early. "Finding early metastasis may be especially of interest in patients with melanoma since the advent of immune modulating drugs such as immune checkpoint inhibitors that can be used to treat metastatic disease with a reasonable toxicity profile," Dr. Esmaeli said.

Refining treatment

Dr. Esmaeli and her colleagues continue to search for ways to improve their patients' outcomes. Toward this end, two clinical trials at MD Anderson are under way to refine the use of SLNB. One trial recently completed its enrollment of patients with melanoma of the eyelid or conjunctiva, and the other is currently enrolling patients with sebaceous carcinoma of the eyelid. The primary endpoints of both trials are to determine the true-positive and false-negative rates of the procedure.

Data from the trials may also clarify which patients should undergo SLNB. "We currently use the criteria for SLNB in cutaneous melanomas—any lesion greater than 1 mm thick—in patients

with eyelid or conjunctival melanomas." Dr. Esmaeli said. "But in conjunctival melanomas, for example, we've never seen a primary tumor less than 2 mm thick that had a positive sentinel lymph node. Conjunctival melanomas are rare, so our patient numbers are not large enough to draw a definitive conclusion; but it seems likely

that the cutoff point for SLNB in conjunctival melanomas should be 2 mm."

Likewise, data from the trial of SLNB in sebaceous carcinoma of the eyelid could confirm clinical observations. "Sebaceous carcinoma is a rare cancer, but I've treated 80 patients with it in my 17 years here at MD Anderson," Dr. Esmaeli said. "Based on the natural history of that cancer and our observations to date, eyelid sebaceous carcinomas of category T2b or higher—based on the American Joint Committee on Cancer seventh edition criteria for eyelid carcinomas—seem to have the highest risk of nodal metastasis."

Related studies by Dr. Esmaeli—in collaboration with Michael Tetzlaff, M.D., Ph.D., an assistant professor in the Department of Pathology, and other colleagues—seek to refine the treatment of sebaceous carcinoma of the eyelid. "We've done some RNA sequencing of sebaceous carcinoma, and we're doing mutational analysis to look for mutations that are potentially targetable in patients with metastatic disease," Dr. Esmaeli said.

Together, these studies are adding to a body of research that, combined with clinical experience, is elucidating the understanding and treatment of cancers of the eyelid and conjunctiva. ■

FOR MORE INFORMATION

Dr. Bitá Esmaeli.....713-792-4457
Dr. Victor Prieto.....713-792-3187

For more information about clinical trials of sentinel lymph node biopsy in conjunctival and eyelid tumors, visit www.clinicaltrials.org and select study GSP00-106 or 2008-0266.

"Other" Health Risks from Smoking

Besides cancer, tobacco causes many diseases



Smoking is widely known to cause cancers of the lungs, digestive system, liver, and other organs, but tobacco smoke poses many other threats. Tobacco smoke contains more than 7,000 chemicals and compounds; 70 of these cause cancer, and hundreds are dangerous in other ways to smokers and to those around them.

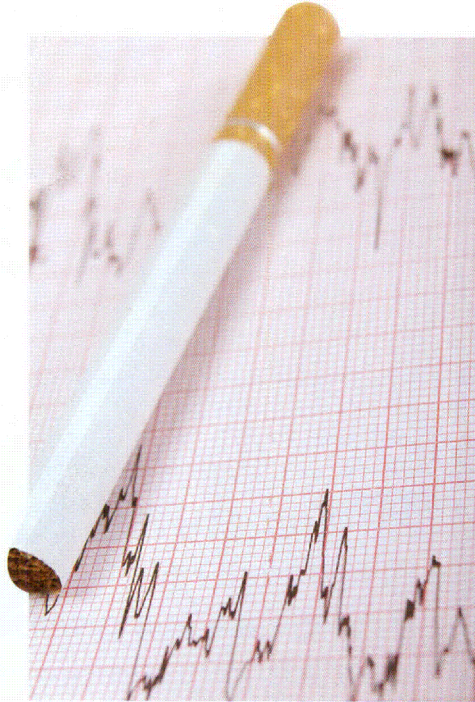Risks to smokers

Smokers have a greater risk of heart disease than do nonsmokers. This is because tobacco smoke causes blood vessels to thicken and narrow, resulting in high blood pressure and damage to the walls of veins and arteries. Smoking also causes the platelets in the blood to congeal and form clots, which line the walls of blood vessels and block the steady flow of blood. Coronary heart disease occurs when these clots form a plaque along the walls of the heart's arteries, cutting off the blood supply and triggering a heart attack. Peripheral heart disease is caused by clotting in the legs or arms. If left untreated, peripheral heart disease can cause cramping, pain, and fatigue in the limb and eventually gangrene, which may require amputation.

The combination of high blood pressure and blood clotting from tobacco smoke can also induce a stroke, where loss of blood or ruptured blood vessels in the brain result in cell death.

Smoking also has been linked to type 2 diabetes, and the likelihood of developing the disease increases with the number of cigarettes smoked per day. Smoking can also worsen conditions such as nerve damage and kidney disease in people who already have diabetes. In addition, smoking can trigger autoimmune disorders such as Crohn disease and rheumatoid arthritis, where the immune system mistakenly attacks the body's own tissues.

The chemicals in smoke can also affect vision. Smoking doubles the risk of developing age-related macular degeneration, a weakening of the central retina



in the eye that leads to loss of vision. Smoking also increases the chances of cataracts and optic nerve damage.

Risks to nonsmokers

In addition to its extensive list of harmful effects to the smoker, tobacco smoke also endangers others. Pregnant women who smoke place their babies at risk for complications such as tissue damage, premature delivery, and death. Nicotine and carbon monoxide from tobacco smoke inhaled by pregnant women are especially harmful to fetuses, constricting the flow of blood and choking off their oxygen supply. Babies born to mothers who smoke have lower birth weights as a result of their underdeveloped bodies, increasing the risk of heart defects, lung damage, and impaired brain development. Finally, smoking while pregnant increases the chances of miscarriage and stillbirth. Yet despite the severe consequences, studies by the U.S. Centers for Disease Control and Prevention (CDC) indicate that less than half of smokers who become pregnant quit during pregnancy.

Parents who smoke also put their children at risk from secondhand smoke.

Babies are especially vulnerable because the chemicals in tobacco smoke constrict their blood vessels and interfere with their brains' ability to regulate breathing. As a result, babies who live with a smoker are two to four times more likely to die from sudden infant death syndrome. In addition, growing up with a smoker increases a child's chances of developing bronchitis, pneumonia, and asthma. Even if a child with asthma does not live with a smoker, exposure to secondhand smoke can trigger asthma attacks, and frequent exposure increases the number and severity of these attacks.

Among adults, exposure to secondhand smoke can pose health risks similar to those of smoking. Frequent exposure increases the chances of cardiovascular disease by 25%–30% and the risk of stroke by 20%–30%. Individuals with heart disease risk having a heart attack when even briefly exposed to secondhand smoke because the smoke immediately constricts their blood vessels.

Risk of death

CDC statistics indicate that the average loss of lifespan for smokers is 13.2 years for men and 14.5 years for women. Smoking is the leading cause of preventable death in the United States, causing an estimated 480,000 deaths annually. Of those deaths, 41,000 are linked directly to secondhand smoke. If you smoke, committing yourself to breaking the habit could be one of the most important decisions you ever make, for yourself and for others. ■

– C. Graber

FOR MORE INFORMATION

- Ask your doctor
- Call askMD Anderson at 877-632-6789
- Visit the CDC Web site at www.cdc.gov/tobacco
- Visit MD Anderson's Tobacco Treatment Program at www.mdanderson.org/quitnow

ADDRESS SERVICE REQUESTED

Anterior Skull Base Tumors

[Continued from page 4]

are based on research by Lauren Byers, M.D., an assistant professor in the Department of Thoracic/Head and Neck Medical Oncology, showing that PARP can be a target in small cell lung cancer, which is a neuroendocrine carcinoma. Immune checkpoint inhibitors, which have shown benefit against a variety of malignancies, might also benefit a subset of patients with skull base carcinomas.

New tools, new horizons

In addition to identifying novel treatment approaches, MD Anderson researchers are developing a range of tools to begin probing the biology of malignant skull base tumors.

"We are fighting a biology that frankly we do not entirely understand," Dr. DeMonte said. "Improvements in our ability to cure these tumors will only be realized when we can unravel the biology of specific tumor cells."

Chief among these developments is a sinonasal undifferentiated carcinoma cell line—the first line of skull base tumor cells to be isolated, grown, cultured, and maintained.

"The cell line is important because we can start screening drugs and see which ones impair the cancer cells' viability. We can also inject the cells in mice and learn about the biology of the tumor," Dr. Ferrarotto said. "And if we can generate solid preclinical data and identify promising therapeutic agents, we will have more leverage to propose clinical trials for this rare disease subgroup and

"If we need to give a high radiation dose to achieve disease cure without compromising the surrounding tissue, we would consider proton therapy."

— Dr. Steven Frank

have a greater potential to improve patients' outcomes."

Researchers have also developed a mouse model for skull base tumors, which can be used to study various aspects of these tumors in vivo. In addition, comprehensive gene analyses have characterized the genomic profiles of some sinus cancers. Additional analyses may unlock the codes of these tumors' aggressive behavior and identify targets for therapy.

"It's a pretty exciting time," Dr. Hanna said. "We have a cell line, we have an animal model, and we have genomic data. We're about to enter a whole other dimension of how to get a handle on these tumors." ■

FOR MORE INFORMATION

Dr. Franco DeMonte713-563-8706
Dr. Renata Ferrarotto713-745-6774
Dr. Steven Frank713-563-8489
Dr. Ehab Hanna713-745-1815

OncoLog®

The University of Texas
MD Anderson Cancer Center

President

Ronald A. DePinho, M.D.

Provost and Executive Vice President

Ethan Dmitrovsky, M.D.

Senior Vice President for Academic Affairs

Oliver Bogler, Ph.D.

Director, Department of Scientific Publications

Kathryn Carnes

Managing Editor

Bryan Tutt

Assistant Managing Editors

Sarah Bronson Jill Delsigne Joe Munch

Contributing Editors

Melissa G. Burkett Christopher Graber
Stephanie Deming Mark Picus
Ann M. Sutton

Design

Janice Campbell, The Very Idea®

Editorial Board

Therese Bevers, M.D., Chair Sapna Patel, M.D.
Lyle Green, Vice Chair Naveen Pemmaraju, M.D.
Elizabeth Grubbs, M.D. David Rice, M.D.
Beverly Handy, M.D. Benjamin Smith, M.D.
Dimitrios Kontoyannis, M.D. Randal Weber, M.D.
Andrea Milbourne, M.D. Christopher Wood, M.D.

For questions or comments about *OncoLog*, please email scientificpublications@mdanderson.org or call 713-792-3305. Current and previous issues are available online in English and Spanish at www.mdanderson.org/publications/oncolog.

Made possible in part by a gift from the late Mrs. Harry C. Wiess.

**NATIONAL
CANCER
INSTITUTE**

A Comprehensive Cancer
Center Designated by the
National Cancer Institute

To Refer a Patient

Physicians: To refer a patient or learn more about MD Anderson, contact the Office of Physician Relations at 713-792-2202, 800-252-0502, or www.physicianrelations.org.

Patients: To refer yourself to MD Anderson or learn more about our services, call 877-632-6789 or visit www.mdanderson.org.